

Neurotrophic Ulcer Secondary to 5th and 7th Cranial Nerve Palsies

Category(ies): Cornea

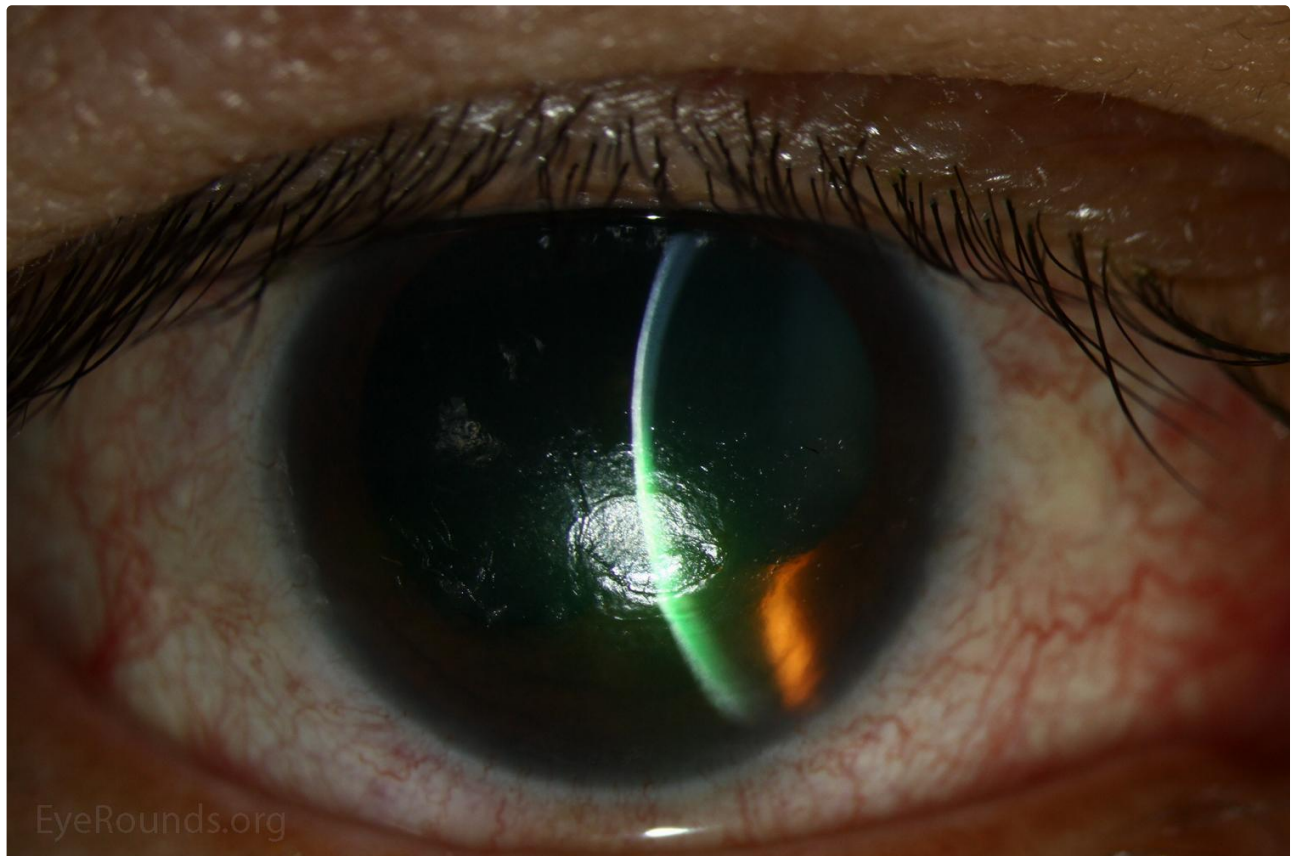
Contributor: [Lindsay McConnell, MD](#) [Luke Lenci, MD](#)

Photographer: Brice Critser, CRA



This is a 51-year-old woman was referred to the ophthalmology clinic from otolaryngology with progressive blurred vision in the right eye after resection of large petroclival meningioma 1 month prior. She had lagophthalmos and incomplete blink with significantly decreased corneal sensation. She was found to have a corneal ulcer with a gray, heaped-up rim, surrounding white blood cell recruitment, and mild corneal edema. She was started on aggressive lubrication and topical antibiotics to prevent secondary bacterial infection with plan for future tarsorrhaphy.

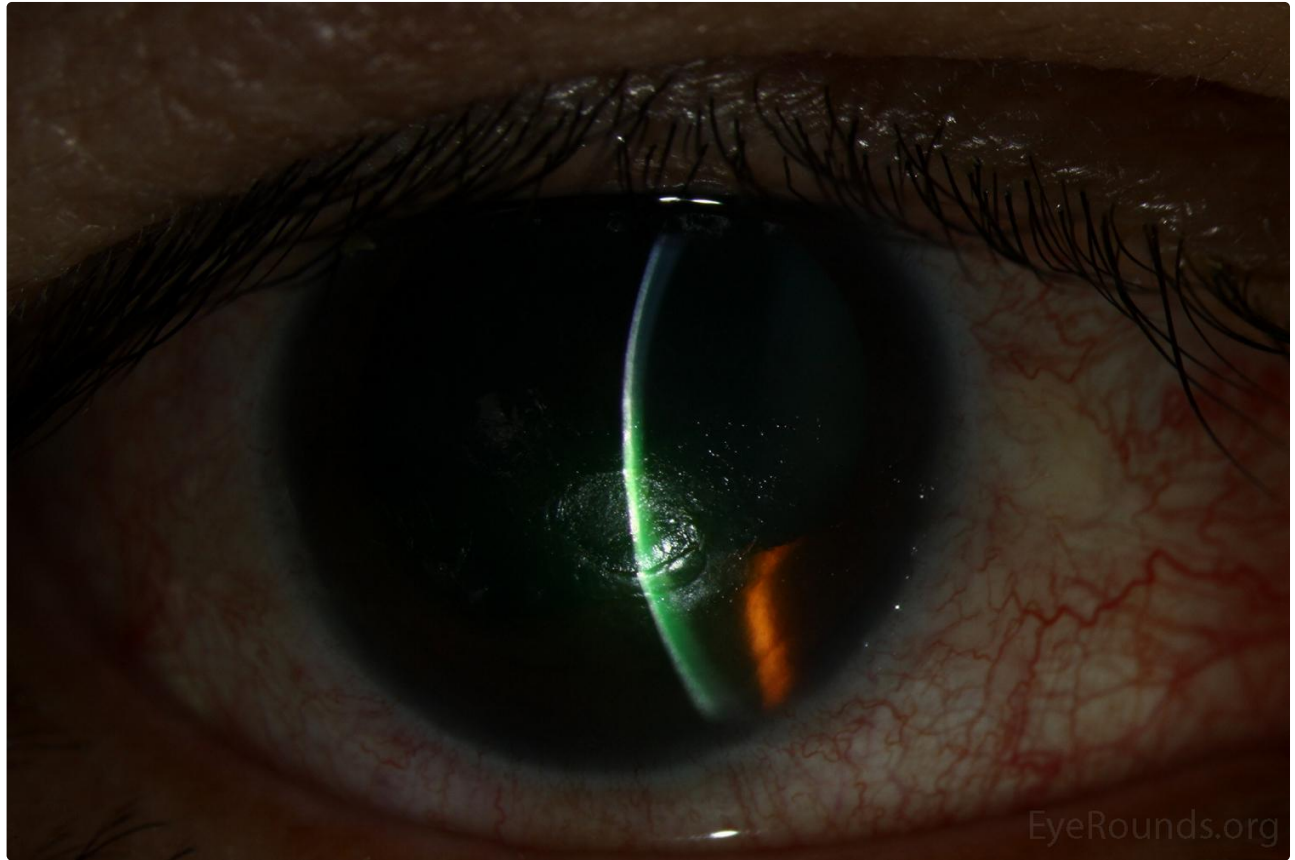
Round or oval-shaped ulcers with grayish, elevated edges are classic for neurotrophic ulcers. In this case the patient had a 5th cranial nerve palsy causing decreased sensation and was also predisposed to exposure given her 7th cranial nerve palsy. The differential for etiology of neurotrophic ulcer also includes cerebrovascular accidents, aneurysms, multiple sclerosis, herpes simplex or herpes zoster keratitis, or toxicity with topical medications such as anesthetics.



EyeRounds.org

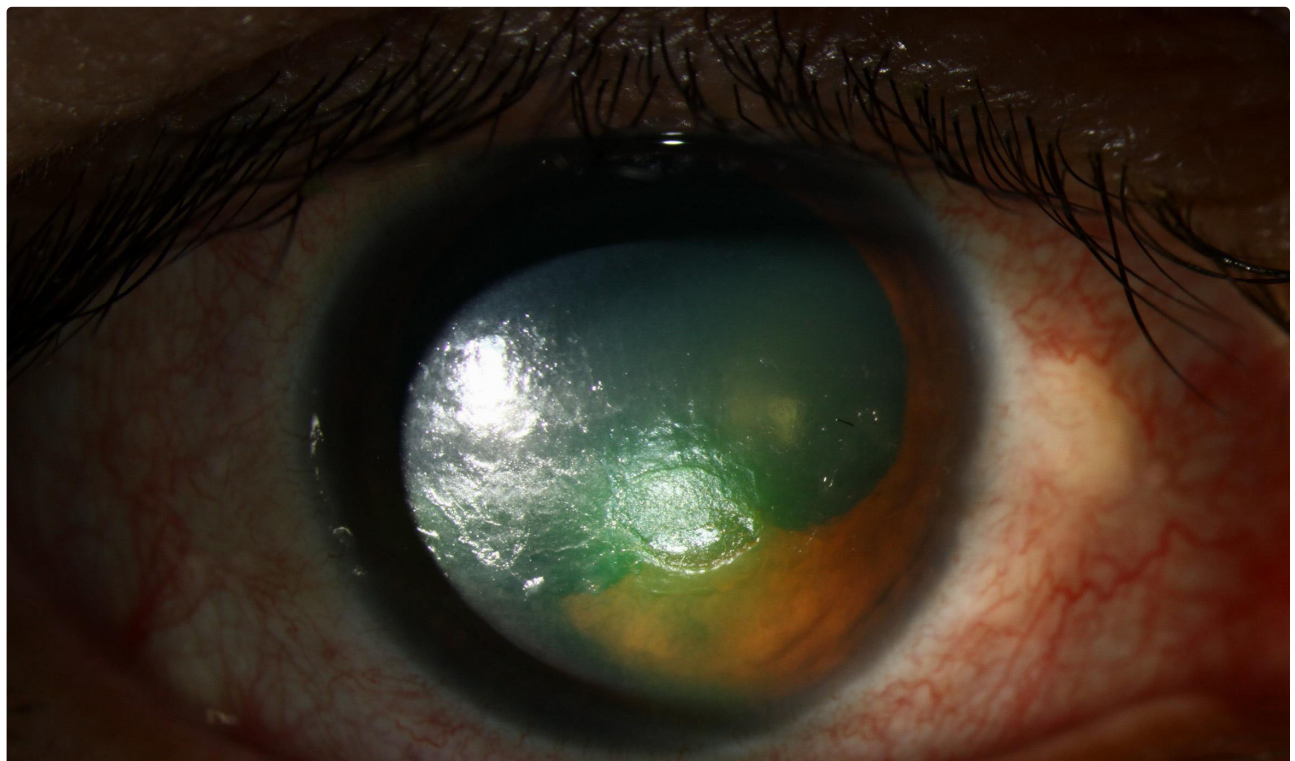
[Enlarge](#)

[Download](#)



[Enlarge](#)

[Download](#)



 Enlarge

 Download

Image Permissions:



Ophthalmic Atlas Images by EyeRounds.org, The University of Iowa are licensed under a [Creative Commons Attribution-NonCommercial-NoDerivs 3.0 Unported License](https://creativecommons.org/licenses/by-nc-nd/3.0/).

Address

University of Iowa
Roy J. and Lucille A. Carver College
of Medicine
Department of Ophthalmology and
Visual Sciences
200 Hawkins Drive
Iowa City, IA 52242

[Support Us](#)

Legal

Copyright © 2019 The University of
Iowa. All Rights Reserved
[Report an issue with this page](#)
[Web Privacy Policy](#) |
[Nondiscrimination Statement](#)

Related Links

[Cataract Surgery for Greenhorns](#)
[EyeTransillumination](#)
[Gonioscopy.org](#)
[Iowa Glaucoma Curriculum](#)
[Iowa Wet Lab](#)
[Patient Information](#)
[Stone Rounds](#)
[The Best Hits Bookshelf](#)

EyeRounds Social Media

Follow



[Receive notification of new cases,
sign up here](#)
[Contact Us](#)
[Submit a Suggestion](#)